

# The Modified Fasanella-Servat Procedure: Description and Quantified Analysis

David B. Samimi, M.D.\*<sup>†</sup>, Melanie H. Erb, M.D.\*<sup>‡</sup>, Christianne J. Lane, Ph.D.<sup>§</sup>, and Steven C. Dresner, M.D.\*<sup>†</sup>

\**Eyesthetica, Oculofacial and Cosmetic Surgery Associates*; <sup>†</sup>*Department of Ophthalmology, Keck School of Medicine, University of Southern California, Los Angeles*; <sup>‡</sup>*Department of Ophthalmology, College of Medicine, University of California at Irvine, Irvine*; and <sup>§</sup>*Department of Preventive Medicine, Division of Biostatistics, Keck School of Medicine, University of Southern California, Los Angeles, California, U.S.A.*

**Purpose:** To describe a modified Fasanella-Servat procedure and nomogram for the correction of minimal amounts of ptosis.

**Methods:** Retrospective review of this modified Fasanella-Servat procedure was performed on 118 eyelids in 86 consecutive patients over 2, 4-year periods by 1 surgeon (S.C.D.). The amount of tarsectomy was based on the amount of ptosis.

**Results:** Mean pre- and postoperative margin-to-reflex distance 1 were +0.7mm and +2.4mm, respectively. One hundred and twelve eyelids (95%) had satisfactory results with postoperative margin-to-reflex distance 1  $\geq$  1.5mm. Eyelid symmetry was achieved in 92% of eyelids to within 0.5mm. There was no incidence of overcorrection, tarsal buckling, or corneal abrasion. One eyelid had a contour deficit. Tarsectomy amount ranged from 2mm to 5mm. Average amount of tarsectomy to eyelid elevation was 2.4:1.

**Conclusions:** The modified Fasanella-Servat procedure is technically easy, time-efficient, and has a low complication rate for the treatment of minimal blepharoptosis (< 2.5mm) with good levator function and negative phenylephrine test. In the authors' hands, the ratio of tarsectomy to eyelid elevation is approximately 2:1. In addition to other techniques such as levator advancement and Müller's muscle conjunctival resection, the modified Fasanella-Servat technique is a useful adjunct to the modern ptosis surgeon's armamentarium.

(*Ophthalm Plast Reconstr Surg* 2013;29:30–34)

In 1961, Fasanella and Servat<sup>1</sup> described their tarsectomy operation for correcting small amounts of blepharoptosis in patients with normal levator function. The Fasanella-Servat (FS) procedure is considered by many surgeons to be fairly reliable and of low technical complexity. Suboptimal results are frequently reported in the literature with success rates ranging from 28% to 61% and frequent reference to contour abnormality and suture keratopathy as surgical complications.<sup>2–5</sup> Most authors have attributed the low success rate to improper surgical technique and poor patient selection.

In 1972, Putterman<sup>6</sup> developed a clamp to replace the use of curved hemostats advocated for fixation of the

tarsalconjunctival complex in the FS procedure. This particular clamp is best known today for its use in the Müller's muscle conjunctival resection (MMCR). The authors use a modified clamp, which features a screw type lock closure mechanism and modified teeth for improved purchase stability of the tarsal plate and minimization of contour abnormalities. Other posterior approaches like the MMCR, also initially described by Putterman and Urist,<sup>7</sup> and further modified and refined by Dresner,<sup>8</sup> have been shown to provide better predictability, with less incidence of late postoperative complications. However, its widespread use is prevented by the sine qua non need of a positive response to the phenylephrine test in order for the procedure to have any predictable effect over the ptosis correction. The FS procedure is well suited for minimal ptosis (< 2.5mm) with a negative phenylephrine test,<sup>9</sup> because the effectiveness of the FS operation is likely independent from its effects on Müller's muscle.

In this study, the authors investigate the efficacy of their modified FS procedure designed to avoid contour abnormality and suture keratopathy for the repair of minimal ptosis amounts.

## MODIFIED FS SURGICAL TECHNIQUE

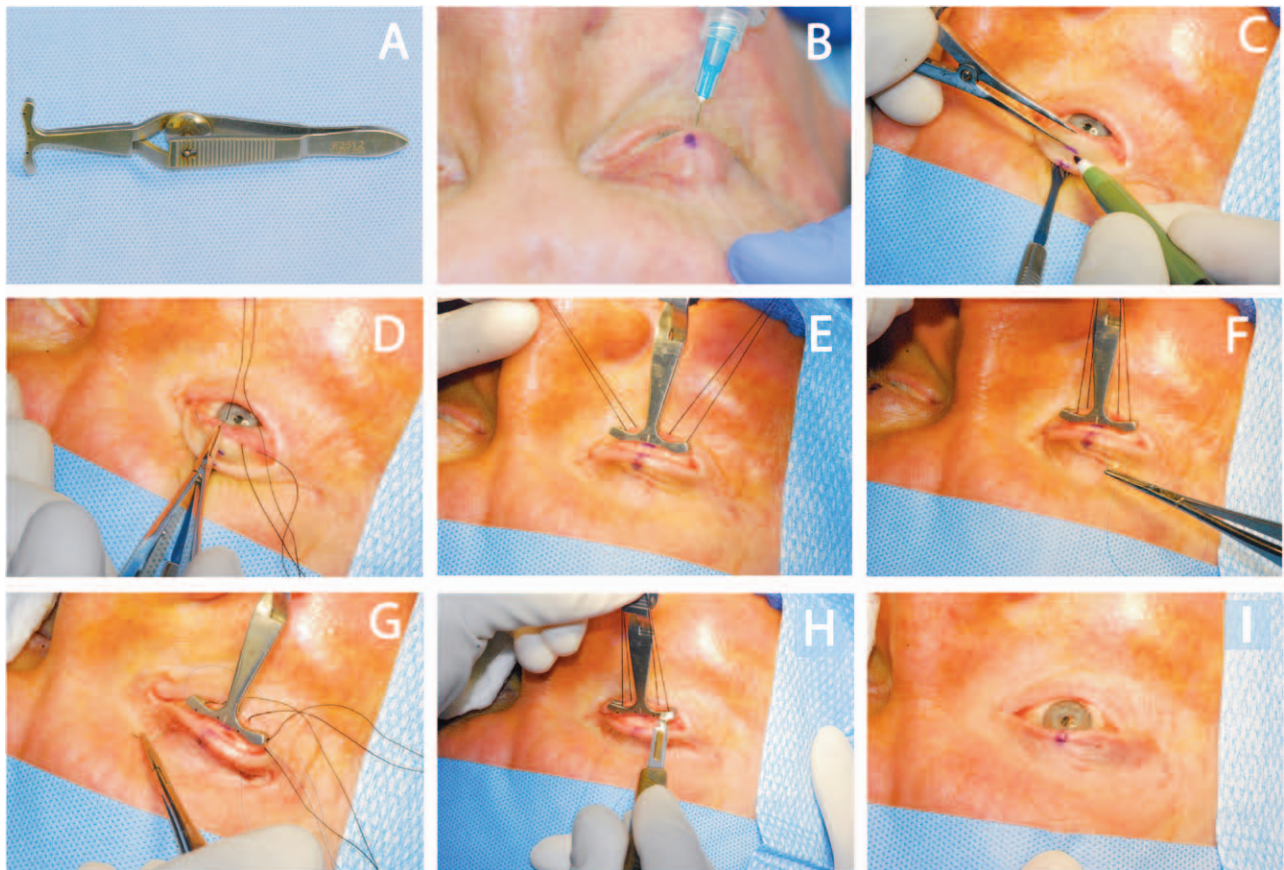
Preoperatively, an upper eyelid mark is placed above the pupillary axis, with the patient sitting upright. A modified Müllerectomy clamp, model no. E2512, with screw type lock closure mechanism (Bausch & Lomb, Rochester, NY, U.S.A.) is included in the sterile instrument tray (Fig. 1A). Topical anesthetic eye drops are instilled in the superior fornix. The upper eyelid is distracted from the globe, and a bent needle is used to inject 1 ml to 2 ml of 1% lidocaine with 1:100,000 epinephrine and hyaluronidase through the palpebral conjunctiva, superior to the tarsus (Fig. 1B). The patient is prepped and draped for surgery. The eyelid is everted over a Desmarres retractor. Calipers are used to measure the proposed resection amount, and the tarsus is marked centrally along the pupillary axis (Fig. 1C). Two-millimeter tarsus should be resected for each millimeter of desired elevation. Two 4-0 silk sutures are placed through the conjunctivotarsal border medially and laterally and tied for traction (Fig. 1D). The Desmarres is removed, and the tissues are elevated via the 2 traction sutures. The clamp is placed over the tarsus and conjunctiva with the maximum height of the clamp centered over the pupillary mark (Fig. 1E). The screw device is turned until the tissues are firmly crushed. A 6-0 prolene suture is passed from the eyelid skin surface approximately 5 mm above the eyelid margin to the conjunctiva under the clamp<sup>10</sup> (Fig. 1F). The prolene is then passed back and forth with approximately 3-mm spacing in a horizontal running fashion below the clamp and

Accepted for publication August 22, 2012.

The authors have no financial or conflict of interest to disclose.

Address correspondence and reprint requests to Steven C. Dresner, M.D., Eyesthetica, 2121 Wilshire Boulevard, Suite 301, Santa Monica, CA 90403-5743. E-mail: steven.dresner@bleph.net

DOI: 10.1097/IOP.0b013e318272d304



**FIG. 1.** Dresner-Uzategui modified müllerectomy clamp and modified Fasanella-Servat surgical technique. **A**, Clamp. **B**, Subconjunctival injection. **C**, Tarsal measurement. **D**, Traction suture placement. **E**, Clamp placement. **F**, Suture from skin to conjunctiva. **G**, Suture run horizontally below clamp and exteriorized. **H**, Traction sutures elevated while excising clamped tissue. **I**, Suture tied loosely over skin.

finally exteriorized through the skin at the other end of the clamp (Fig. 1G). The authors prefer a longer semicircular needle, e.g., P3 equivalent (Ethicon, Somerville, NJ, U.S.A.), to facilitate the pass from conjunctiva to skin. While holding the prolene against the forehead and silk sutures upward with the clamp, the conjunctivotarsal tissues are excised with a no. 15 Bard-Parker blade, using metal-to-metal contact from the blade to the clamp (Fig. 1H). The eyelid is reflected back in its anatomical position, and the suture is tied loosely to itself anterior to the skin in the pretarsal area (Fig. 1I). Any encountered bleeding subsides once the suture is tied. The surgical time is approximately 10 minutes for each upper eyelid. Antibiotic-steroid drops are used postoperatively. The suture is removed in 5 to 7 days by cutting the externalized portion nasally and pulling the suture out laterally.

## METHODS

A Current Procedural Terminology–guided query for Current Procedural Terminology code 67908 (FS procedure) was conducted during all periods of available electronic medical records (Fox Med, San Antonio, TX; NextGen, Horsham, PA, U.S.A.) for one of the authors (S.C.D.). Inclusion criteria consisted of all patients with documentation of the following variables: preoperative margin-to-reflex distance 1 (MRD<sub>1</sub>) in primary gaze, levator excursion, and postoperative MRD<sub>1</sub> measurements with a minimum of at least 2 postoperative follow-up visits at 1 month or longer. Demographics, history of previous ptosis surgeries, and result of the phenylephrine testing (MRDp)<sup>11</sup> were documented. The authors considered any eyelid that did not reach acceptable elevation 5 minutes after superior forniceal instillation of 2.5% phenylephrine as a negative test. Patients undergoing concurrent

blepharoplasty or other upper eyelid procedures were excluded. Informed consent was obtained for each procedure, and the review was Health Insurance Portability and Accountability Act compliant and adhered to the standards of the Declaration of Helsinki.

The change in MRD<sub>1</sub> was calculated as the postoperative MRD<sub>1</sub> at the latest follow up minus the most recent preoperative MRD<sub>1</sub>. Symmetry was measured by comparing the postoperative MRD<sub>1</sub> of both eyelids at the latest follow up. A positive or negative sign was given to the symmetry value based on what the final MRD<sub>1</sub> result of the operative eyelid was relative to anticipated result using the author's 2:1 tarsectomy to eyelid elevation ratio. Actual tarsectomy to eyelid elevation ratio was calculated by dividing the amount of tarsus resected by the change in preoperative versus postoperative MRD<sub>1</sub> in each patient. To assess the influence of age, prior surgery, preoperative values, levator and resection amount on outcomes (difference and ratio), univariate and multivariate mixed-effects modeling were performed to account for variability in results due to intraindividual differences. All analyses were performed by one of the authors (C.J.L.) using SPSS (IBM, Armonk, NY, U.S.A.) version 20 software;  $\alpha = 0.05$ .

## RESULTS

The database search yielded 2 consecutive series from June 1997 to November 2000 (Fox Med) and May 2005 to September 2011 (NextGen). A total of 118 FS surgeries from 86 patients were identified. Demographic and clinical data are shown in the Table. There were no differences in the patient characteristics between the series, and data were combined for analysis.

Thirty-four percent of patients had a history of prior ptosis surgery, the majority through a posterior approach (MMCR).

Clinical characteristics	
<b>Total cohort</b>	
Patients (n = 86)	
Eyelids (n = 118)	%
Gender	
Men	42
Women	58
Prior ptosis surgery	
No	66
Yes	34
Anterior	10
Posterior	22
Unknown	2
Bilateral surgery	37
Laterality	
Right	44
	<b>Mean (SD)</b>
Age (range, 5–95)	71 years (19)
Follow up (range, 4–80)	9 weeks (10)
Levator function	14 mm (3)
MRD1 preoperative	0.7 mm (0.7)
MRD1 postoperative	2.4 mm (0.8)
MRD1 change	1.7 mm
Ratio:Resection/change	2.4 (1)

MRD1, margin-to-reflex distance 1; SD, standard deviation.

Those who had previous MMCR surgery did not undergo phenylephrine testing. All other patients had a negative phenylephrine test. Mean pre- and postoperative MRD<sub>1</sub> were +0.7 mm and +2.4 mm, respectively. One hundred and twelve eyelids (95%) had satisfactory results with postoperative MRD<sub>1</sub> ≥ 1.5 mm (Fig. 2). Of the 6 eyelids with residual ptosis, 4 were elected for reoperation and were repaired to patient satisfaction with external levator advancement. Eyelid symmetry was achieved in 92% of eyelids to within 0.5 mm (Fig. 3). There was no incidence of overcorrection, tarsal buckling, instability, or corneal abrasion. One eyelid had a contour deficit.

Tarsectomy amount ranged from 2 mm to 5 mm. Mean amount of tarsectomy resection to eyelid elevation was 2.4:1

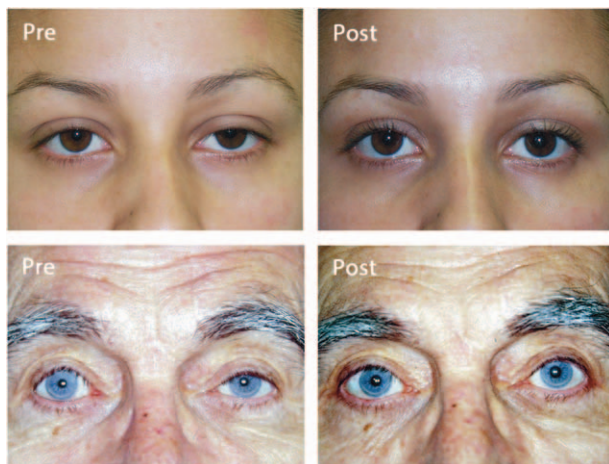


FIG. 2. Clinical photographs showing pre- and postoperative modified Fasanella-Servat procedure. **Above**, Bilateral asymmetric ptosis treated with 2-mm tarsectomy on the right and 4-mm tarsectomy on the left. **Below**, Four-millimeter tarsectomy in the left for 2 mm of lift.

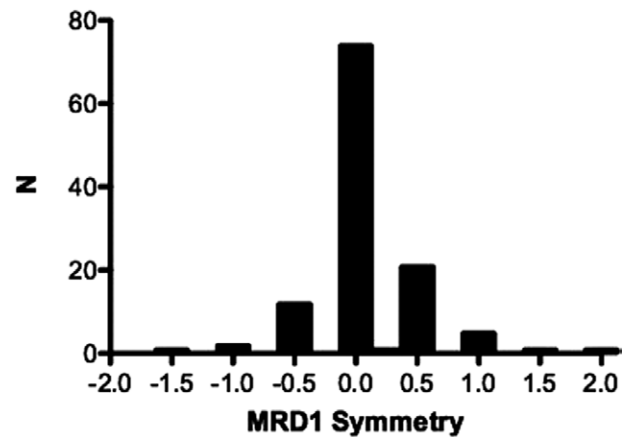


FIG. 3. Postoperative eyelid symmetry.

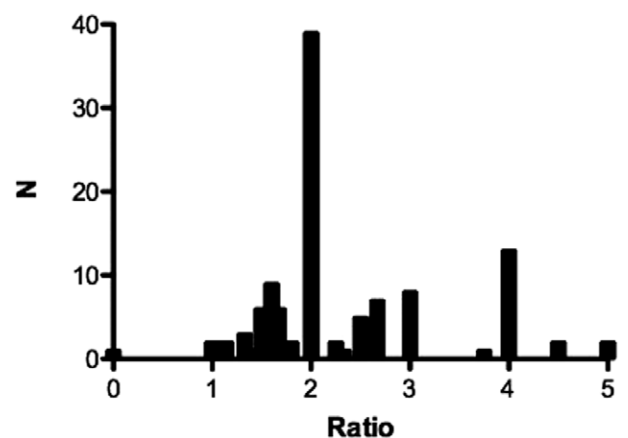


FIG. 4. Tarsectomy amount to eyelid elevation ratio.

with 2:1 being the most frequent ratio (Fig. 4). There were no correlations between ratio predictability and age ( $r = -0.13$ ), prior surgery, preoperative MRD<sub>1</sub>, resection amount, or levator function (all  $p$  values  $> 0.15$ ). In univariate analyses, significant predictors of greater change in MRD<sub>1</sub> included older age ( $p = 0.003$ ), lower preoperative MRD<sub>1</sub> value ( $p < 0.001$ ), and larger resection amount ( $p < 0.001$ ). These 3 variables remained significant predictors, even when adjusting for each other in the model.

## DISCUSSION

This study found that the modified FS is a technically easy, time-efficient procedure with low complication rate for the treatment of minimal blepharoptosis ( $< 2.5$  mm) with good levator function and negative phenylephrine test. In the authors' hands, the resection nomogram is approximately 2:1 for tarsectomy resection to amount of ptosis correction, with a maximum tarsectomy of 5 mm. In one third of the patients, the technique was used secondarily to augment results of previous ptosis repair.

Fasanella and Servat originally described their procedure using 2 curved hemostats. Placing these hemostats can be cumbersome and is assistant-dependent, often leading to misplacement and postoperative contour abnormalities. The success rate of the operation has been quoted from 28% to 61.6% or 94.6% depending on the severity of the ptosis and include multiple references to eyelid contour abnormalities such as upper eyelid peaking and tarsal buckling,<sup>2-4,10-16</sup> and need for postoperative



adjustment.<sup>15</sup> The use of a Müllerectomy clamp with the authors' surgical technique facilitates a straight-forward stabilization of the tarsus and has many advantages over the use of hemostats or forceps for this purpose. Most clamps have an arched design, which when centered on the previously marked pupillary eyelid margin facilitates a controlled, naturally arched cut, using the no.15 blade metal to metal against the clamp. The teeth on the modified Müllerectomy clamp used by the authors have been moved closer to the arch edge, enabling smaller, more precise resections. The screw type lock mechanism provides for a variable amount of crush depending on thickness of the tarsus, encouraging hemostasis and preventing slippage of the clamp. Use of traction sutures marked, placed, and held completely by the surgeon during excision of tarsus eliminates the dependence on a surgical assistant for consistent tension and orientation of the hemostats during excision. There was 1 contour abnormality in 118 eyelids in this study, and the authors believe the above improvements to the previously described FS procedure account for this lower rate.

Histopathologic evaluation of specimens studied from FS procedures has failed to show smooth muscle in most patients; nevertheless, these patients had equally successful ptosis correction.<sup>17</sup> The success of the procedure in the subset of patients with a negative phenylephrine test may be attributed to the fact that the effect of the FS procedure does not depend on the excision and shortening of Müller's muscle, but instead likely a combination of vertical posterior lamellar shortening, secondary contraction of the wound, and plication or advancement of the Müller's smooth muscle-levator aponeurosis complex on the tarsus.<sup>16,17</sup>

Although the original article recommended the FS procedure for the correction of 3-mm to 4-mm ptosis, the authors' findings do not support the use of the procedure for this degree of ptosis. In the authors' hands, the maximum amount of ptosis correction is 2.5 mm; this allows a maximum of 5-mm tarsectomy while ensuring an adequate amount of remaining tarsus to prevent postoperative buckling or instability, and resection nomogram of 2:1 for tarsectomy to amount of ptosis correction.

The FS procedure can be performed on patients with or without a positive phenylephrine test.<sup>17</sup> However, the authors advocate the use of MMCR in patients with a positive phenylephrine test, because these patients are usually better served with the excellent predictability of the nomogram described and used for this surgical technique.<sup>8</sup> Phenylephrine testing is not useful in patients who would generally be poor candidates for MMCR surgery such as those with history of prior MMCR.

The FS procedure was originally described using plain gut suture. This may lead to suture keratopathy. In contrast to plain gut, the authors have found that prolene does not irritate the cornea, and with exteriorization of the knot on the eyelid skin,<sup>10</sup> corneal irritation is prevented. There were no cases of suture keratopathy or need for bandage contact lens in the authors' series of 118 patients.

The authors' study attempts to produce a standardized nomogram for the FS procedure. Buckman et al.<sup>17</sup> described a large series of patients who underwent the FS procedure performed by 4 surgeons. They found that most patients had absent to minimal amounts of Müller's muscle in their histopathologic specimens; yet, these patients had equal success in their postoperative results for their ptosis correction. The authors could not correlate the amount of tarsoconjunctival resection to the amount of ptosis correction. Two factors may explain the inability to detect a correlation. First, patient cohorts from 4 surgeons were combined with no mention of standardized technique. Second, tarsectomy amount was attained by measuring postoperative specimen, which likely had undergone variable amounts of mechanical shortening after excision or fixative agent

contraction. Gupta et al.<sup>5</sup> published a series of 50 patients who had ptosis correction using the FS procedure with a standard resection formula of 3 mm as described by Fasanella and Servat in their original procedure. Gupta et al. quantified their postoperative results using the change in preoperative and postoperative eyelid fissure height. Because no amount of ptosis could be accurately identified using this method and all the patients treated received the same amount of tarsectomy, no correlation analysis to determine a surgical nomogram could be derived from this study.

Betharia et al.<sup>18</sup> previously reported the use of traction sutures and tarsus excision of double the amount of desired ptosis correction. This ratio was not confirmed with actual MRD<sub>1</sub> measurements. In the series of 14 patients examined, there were 3 corneal abrasions and 2 contour abnormalities. The authors believe this higher rate of complications likely relates to the use of absorbable catgut suture and tarsoconjunctival complex excision without a clamp.

One third of the eyelids that underwent the FS procedure in the authors' study were reoperations after prior ptosis surgery. Two thirds of these were after a previous MMCR and one third after anterior levator advancement. No statistically significant difference in efficacy or tarsectomy to resection ratio between FS surgeries done as a primary versus secondary procedure was found. This procedure has become an invaluable tool for the authors to easily and reliably correct small amounts of asymmetry that arise after other primary ptosis repairs.

Complications inherent to the proposed technique include overcorrection, undercorrection, eyelid asymmetry, and the rare contour abnormality. Overcorrections can usually be treated by early removal of the prolene suture and by digital massage.<sup>15</sup> In the authors' series, there were no overcorrections that required early suture removal. Undercorrections will need further surgical intervention using external levator aponeurotic advancement as occurred successfully in 4 patients in the authors' study.

Limitations of the authors' study arise from its retrospective, noncomparative design. The relatively short-term follow up based on the referral pattern of the authors' practice is a further limitation. Thus, consecutive ptosis and late contour abnormalities may be under-reported.

The modern ptosis surgeon benefits from a variety of ptosis repair options. The modified FS procedure is technically easy, time-efficient, minimizes contour abnormalities, and has a low complication rate for the treatment of minimal blepharoptosis (< 2.5 mm) with good levator function and negative phenylephrine test. In the authors' hands, the ratio of tarsectomy to eyelid elevation is approximately 2:1. In addition to other techniques such as levator advancement and MMCR, the modified FS procedure is a useful adjunct to the modern ptosis surgeon's armamentarium.

## ACKNOWLEDGMENTS

The authors acknowledge the Keck School of Medicine at the University of Southern California and the Clinical and Translational Science Institute for assistance with statistical analysis.

## REFERENCES

1. Fasanella RM, Servat J. Levator resection for minimal ptosis: another simplified operation. *Arch Ophthalmol* 1961;65:493-6.
2. Wiggs EO. The Fasanella-Servat operation. *Ophthalmic Surg* 1978;9:48-57.
3. Carroll RP. Preventable problems following the Fasanella-Servat procedure. *Ophthalmic Surg* 1980;11:44-51.
4. Sampath R, Saunders DC, Leatherbarrow B. The Fasanella-Servat procedure: a retrospective study. *Eye (Lond)* 1995;9 (Pt 1):124-5.

5. Gupta VP, Aggarwal R, Mathur SP. Blepharoptosis repair by modified sutureless Fasanella-Servat Operation (F.S.O)—a large series of 50 cases. *Indian J Ophthalmol* 1992;40:86–9.
6. Putterman AM. A clamp for strengthening Müller's muscle in the treatment of ptosis. Modification, theory, and clamp for the Fasanella-Servat ptosis operation. *Arch Ophthalmol* 1972;87:665–7.
7. Putterman AM, Urist MJ. Müller's muscle-conjunctival resection ptosis procedure. *Ophthalmic Surg* 1978;9:27–32.
8. Dresner SC. Further modifications of the Müller's muscle-conjunctival resection procedure for blepharoptosis. *Ophthalm Plast Reconstr Surg* 1991;7:114–22.
9. Glatt HJ, Fett DR, Putterman AM. Comparison of 2.5% and 10% phenylephrine in the elevation of upper eyelids with ptosis. *Ophthalmic Surg* 1990;21:173–6.
10. Bodian M. A revised Fasanella-Servat ptosis operation. *Ann Ophthalmol* 1975;7:603–5.
11. Uzcategui N, Dresner SC, Burnstine MA. MRDf and MRDp: two new measurements in evaluating upper eyelid malpositions. Presented at Doheny Days Conference, Los Angeles, CA, 2002.
12. Laming L. Blepharoptosis correction with the sutureless Fasanella-Servat operation. *Arch Ophthalmol* 1977;95:671–4.
13. Weiss IS, Shorr N. Tarsal buckling after sutureless Fasanella-Servat procedures. *Am J Ophthalmol* 1980;90:377–9.
14. Fox SA. A modified Fasanella-Servat procedure for ptosis. *Arch Ophthalmol* 1975;93:639–40.
15. Rosenberg C, Lelli GJ, Jr, Lisman RD. Early postoperative adjustment of the Fasanella-Servat procedure: review of 102 consecutive cases. *Ophthalm Plast Reconstr Surg* 2009;25:19–22.
16. Pang NK, Newsom RW, Oestreicher JH, et al. Fasanella-Servat procedure: indications, efficacy, and complications. *Can J Ophthalmol* 2008;43:84–8.
17. Buckman G, Jakobiec FA, Hyde K, et al. Success of the Fasanella-Servat operation independent of Müller's smooth muscle excision. *Ophthalmology* 1989;96:413–8.
18. Betharia SM, Grover AK, Kalra BR. The Fasanella-Servat operation: a modified simple technique with quantitative approach. *Br J Ophthalmol* 1983;67:58–60.