

Multipurpose Conical Orbital Implant in Evisceration

Harry Marshak, M.D., and Steven C. Dresner, M.D.

Doheny Eye Institute, Keck School of Medicine, University of Southern California, Los Angeles, California, U.S.A.

Purpose: To evaluate the safety and efficacy of the porous polyethylene multipurpose conical orbital implant for use in evisceration.

Methods: A retrospective review of 31 eyes that underwent evisceration and received the multipurpose conical orbital implant. The orbits were evaluated at 1 week, 1 month, and 6 months after final prosthetic fitting for implant exposure, superior sulcus deformity, and prosthetic motility.

Results: There were no cases of extrusion, migration, or infection. All patients had a good cosmetic result after final prosthetic fitting. Prosthetic motility was good in all patients. Exposure developed in one eye (3%) and a superior sulcus deformity developed in one eye (3%).

Conclusions: Placement of an multipurpose conical orbital implant in conjunction with evisceration is a safe and effective treatment for blind painful eye that achieves good motility and a good cosmetic result.

Evisceration has proved to be effective for the treatment of blind painful eye from phthisis bulbi or endophthalmitis. By retaining the sclera in its anatomic natural position, evisceration has the advantage of allowing the insertions of the extraocular muscles to remain intact, promoting better motility. It also allows for the surgical closure of sclera anterior to the implant, providing a strong barrier against implant exposure.

After evisceration or enucleation, the postoperative anophthalmic orbit is at risk for the development of socket abnormalities including enophthalmos, retraction of the upper eyelid, deepening of the superior sulcus, backward tilt of the prosthesis, and stretching of the lower eyelid.¹ These problems are generally thought to be secondary to orbital volume deficiencies.

The multipurpose conical porous polyethylene orbital implant (MCOI) (Porex Medical) was designed to address these issues. The conical shape more closely matches the anatomic shape of the orbit than a spherical implant (Fig. 1). The wider anterior portion, combined with the narrower and longer posterior portion, allows for a more complete and natural replacement of the lost orbital volume. This shape reduces the risk of superior sulcus deformity and puts more volume within the muscle cone.

Although it is effective in enucleation, the MCOI is particularly well suited to use in evisceration. It con-

forms anteriorly to the sclera to be closed over it, without crowding the fornices, and extends posteriorly through the posterior sclerotomy, providing needed volume to the posterior orbit.

METHODS

A retrospective analysis was conducted of 31 eyes that underwent evisceration between June 1999 and October 2003. All eyes received an MCOI of either 18 mm or 20 mm diameter. Twenty-four eyes underwent evisceration for phthisis bulbi (blind painful eye), 7 eyes underwent evisceration for endophthalmitis, and 6 eyes (19%) underwent concomitant temporalis fascia patch graft for reinforcement. The orbits were evaluated at 1 week, 1 month, and 6 months after final prosthetic fitting for implant exposure and superior sulcus deformity. Prosthetic motility was evaluated in the four primary meridians and was described as good if movement was beyond 15 degrees from primary position.²

Surgical Technique. A 360-degree peritomy was made in the conjunctiva at the limbus, with care taken to preserve all available conjunctiva. Curved Stevens scissors were used to dissect between Tenon fascia and sclera in the four quadrants between the rectus muscles. The cornea was then excised with a 360 degree keratectomy. Evisceration spoons were used to remove all intraocular contents until all uveal tissue was scraped free of the scleral pocket. Hemostasis was obtained with monopolar cautery, specifically at the optic nerve and vortex veins. A 360 degree sclerotomy was made around the optic nerve with cutting cautery. Relaxing incisions were made in the posterior sclera in the four quadrants between the rectus muscles from the posterior sclerotomy to the equator (Fig. 2a). Anterior sclerotomies were made at the 4 o'clock and 10 o'clock positions to allow insertion of the implant. An orbital sizing set was used to determine the needed orbital volume, and the appropriately sized MCOI was placed in the scleral pocket

Address correspondence and reprint requests to Dr. Harry Marshak, 520 California Avenue, #7, Santa Monica, CA 90403, U.S.A. E-mail: hmarshak@aol.com

Accepted for publication March 23, 2005.

Steven Dresner, M.D., is a paid consultant for Porex Medical.

DOI: 10.1097/01.iop.0000173191.24824.40




FIG. 1. The multipurpose conical porous polyethylene orbital implant (MCOI) (Porex Medical).

after being soaked in antibiotic solution (Fig. 3). The sclera was closed with 5-0 Vicryl interrupted sutures. The Tenon fascia was closed in 2 layers of 5-0 Vicryl interrupted sutures. The conjunctiva was closed with 6-0 plain gut running suture. An acrylic conformer was placed in the fornices. A tarsorrhaphy was placed using 4-0 silk suture and foam bolsters.

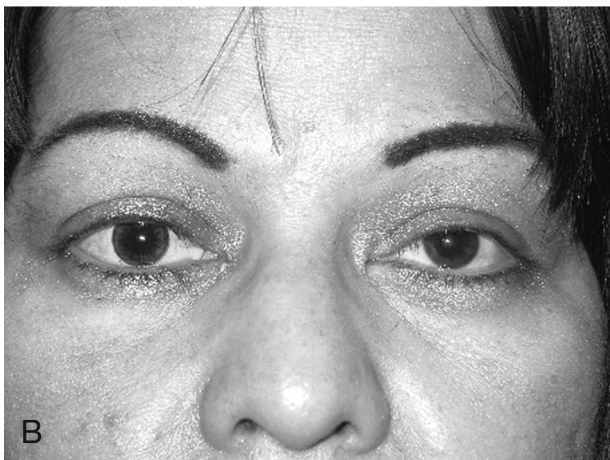
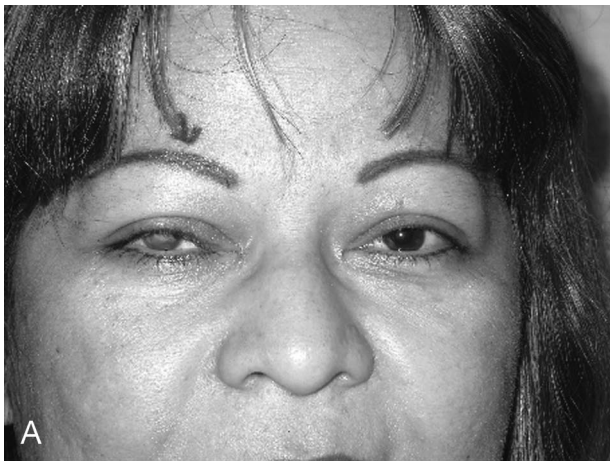
FIG. 2. A, Preoperative photo of a patient with phthisical right eye. B, After evisceration of the right eye with implantation of the multipurpose conical porous polyethylene orbital implant.

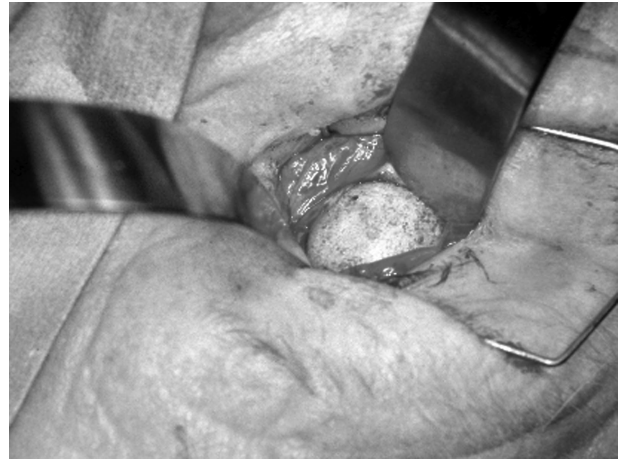

FIG. 3. Orbital sizing set was used to determine needed orbital volume; appropriately sized multipurpose conical porous polyethylene orbital implant was placed in the scleral pocket after being soaked in antibiotic solution.

RESULTS

Thirty-one patients underwent evisceration over a 3-year period. Thirty patients had no superior sulcus deformity. Prosthetic motility was good in all patients. Exposure developed in one eye (3%). This patient required a temporalis fascia graft to achieve closure. A superior sulcus deformity developed in one other eye (3%). This patient was reimplemented with a larger MCOI, with resolution of the deformity. There were no cases of extrusion, migration, or infection (Table). All patients had a good cosmetic result after final prosthetic fitting (Fig. 2b).

DISCUSSION

Evisceration has been shown to be a safe and effective treatment for blind painful eye.³ The advantages of evisceration over enucleation are because the scleral pocket and extraocular muscle attachments are left intact during the procedure. This allows for superior motility, improved cosmesis, better hemostasis, and shorter operating time.

In addition to practical limitations on prosthesis size,⁴ orbital volume deficiency after evisceration or enucleation is secondary to the fact that orbital implants cannot adequately replace the natural volume of the globe. The most common consequence of insufficient orbital volume replacement is inferior and posterior displacement of the superior rectus-levator complex, causing a superior sulcus deformity and backward tilting of the prosthesis.⁵ Kaltreider et al.⁶ determined that 70% to 80% of the amount of orbital volume removed must be replaced.

Diagnosis	Patient data			
	No.	Primary reinforcement	Exposure	Superior sulcus deformity
Blind painful eye	24	1	1	0
Endophthalmitis	7	5	0	1

However, the removal of the cornea and anterior chamber, combined with closure of the sclera over the implant, causes a loss of anterior orbital volume that is difficult to restore. Due to the conical shape of the orbit, there are limitations on the size of the spherical implant that can be used. The use of too large a spherical implant can lead to crowding of the fornices and an increased incidence of implant exposure.

The safety of porous polyethylene as a material for orbital implantation has previously been established.⁷ Porous polyethylene allows vascular ingrowth in the implant material, allowing for better integration of the surrounding soft tissue. A large, retrospective study of a spherical porous polyethylene orbital implant had a low exposure rate but did not report rates of superior sulcus deformity.⁸ Rubin et al.² described a conical implant with a superior anterior projection. However, this implant was designed for use in enucleation and is not recommended for use in evisceration.

Compared with a spherical orbital implant, the conical shape of the MCOI more closely matches the anatomic shape of the orbit. A conical implant provides the overall volume equal to that of a spherical implant with a 2 mm larger diameter. The MCOI adds volume to the posterior portion of the implant to make up for the anterior orbital volume lost in evisceration. This added posterior volume serves to prevent against enophthalmos, superior sulcus deformity, and posterior tilting of the prosthesis. Furthermore, the conical shape of the implant within the muscle cone prevents it from interfering with extraocular motility.

The wider anterior portion of the MCOI fills the scleral pocket to give more volume anteriorly, as a natural globe would. This allows for a more complete and natural replacement of the lost orbital volume, both anteriorly and posteriorly, preventing the displacement of the superior muscle complex. The anterior surface of the implant is rounded, to allow for dispersion of the pressure on the anterior closure, and smoother, to prevent erosion.

Creating sclerotomies in the posterior portion of the scleral pocket during evisceration allows the more narrow posterior portion of the implant to be placed in the posterior orbit. The advantage of this is 2-fold. First, by allowing the porous polyethylene to make contact with the orbital soft tissue, it allows vascular ingrowth in the

implant, reducing the risk of extrusion. Second, it allows a larger size of conical implant to be implanted, providing added orbital volume replacement posteriorly, within the muscle cone. This reduces the risk of enophthalmos and superior sulcus deformity.

In this study, the MCOI was used safely and effectively in evisceration, with no cases of extrusion, migration, or infection. No effect on extraocular motility was detected, despite increased volume within the muscle cone. All patients had a good cosmetic result after final prosthetic fitting.

The MCOI was safely used as a primary implant in 7 eyes with endophthalmitis. The safety and efficacy of performing evisceration with primary porous polyethylene implantation for endophthalmitis has previously been reported.⁹ Five of the 7 eyes in this study with endophthalmitis underwent concurrent temporalis fascia graft over the implant to improve strength of the closure.

The MCOI in conjunction with evisceration is a safe and effective treatment for blind painful eye. Eyes undergoing evisceration with implantation of this implant achieve good motility and a good cosmetic result.

REFERENCES

1. Smit TJ, Koornneef L, Zonneveld FW et al. Computed tomography in the assessment of the postenucleation socket syndrome. *Ophthalmology* 1990;97:1347-51.
2. Rubin PA, Popham J, Rumelt S et al. Enhancement of the cosmetic and functional outcome of enucleation with the conical orbital implant. *Ophthalmology* 1998;105:919-25.
3. Levine MR, Pou CR, Lash RH. The 1998 Wendell Hughes Lecture. *Evisceration: is sympathetic ophthalmia a concern in the new millennium?* *Ophthalm Plast Reconstr Surg* 1999;15:4-8.
4. Kaltreider SA. The ideal ocular prosthesis: analysis of prosthetic volume. *Ophthalm Plast Reconstr Surg* 2000;16:388-92.
5. Kronish JW, Gonnering RS, Dortzbach RK et al. The pathophysiology of the anophthalmic socket, II: Analysis of orbital fat. *Ophthalm Plast Reconstr Surg* 1990;6:88-95.
6. Kaltreider SA, Jacobs JL, Hughes MO. Predicting the ideal implant size before enucleation. *Ophthalm Plast Reconstr Surg* 1999;15:37-43.
7. Karesh JW, Dresner SC. High-density porous polyethylene (Medpor) as a successful anophthalmic socket implant. *Ophthalmology* 1994; 101: 1688-96.
8. Blyaydon SM, Shepler TR, Neuhaus RW et al. The porous polyethylene (Medpor) spherical orbital implant: a retrospective study of 136 cases. *Ophthalm Plast Reconstr Surg* 2003;19:364-71.
9. Dresner SC, Karesh JW. Primary implant placement with evisceration in patients with endophthalmitis. *Ophthalmology* 2000; 107: 1661-5.